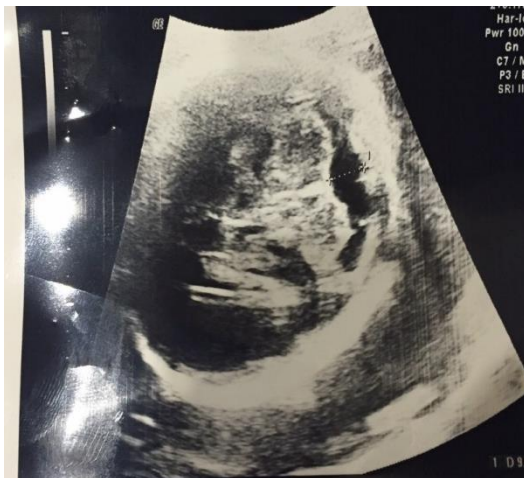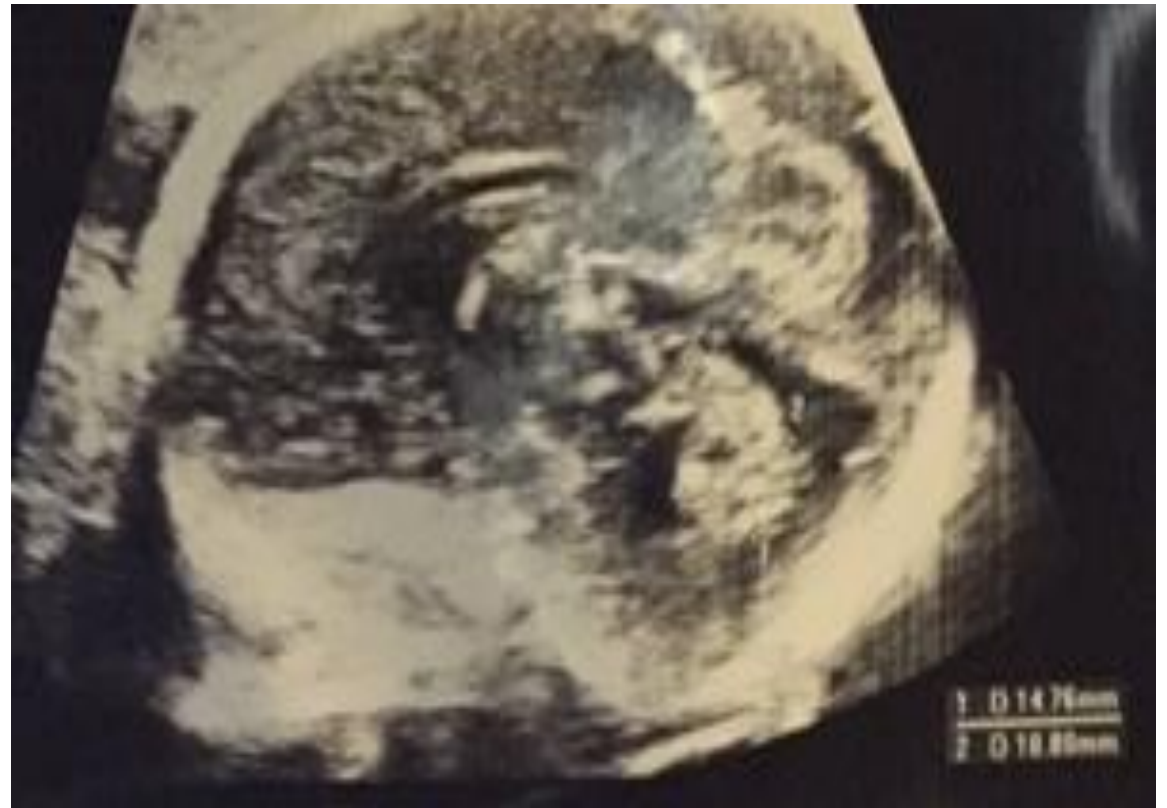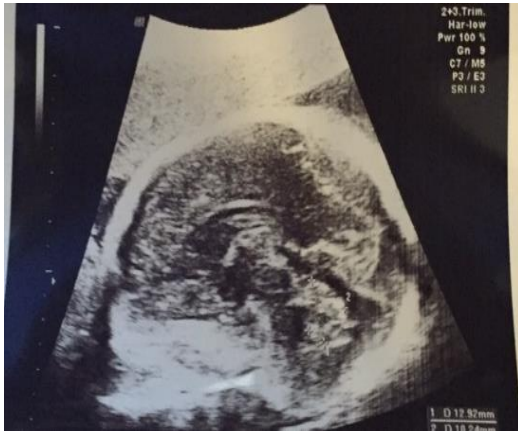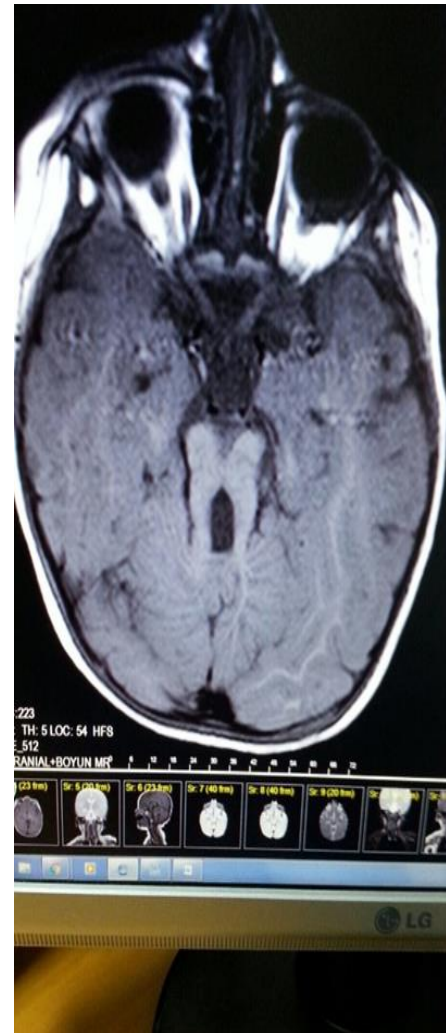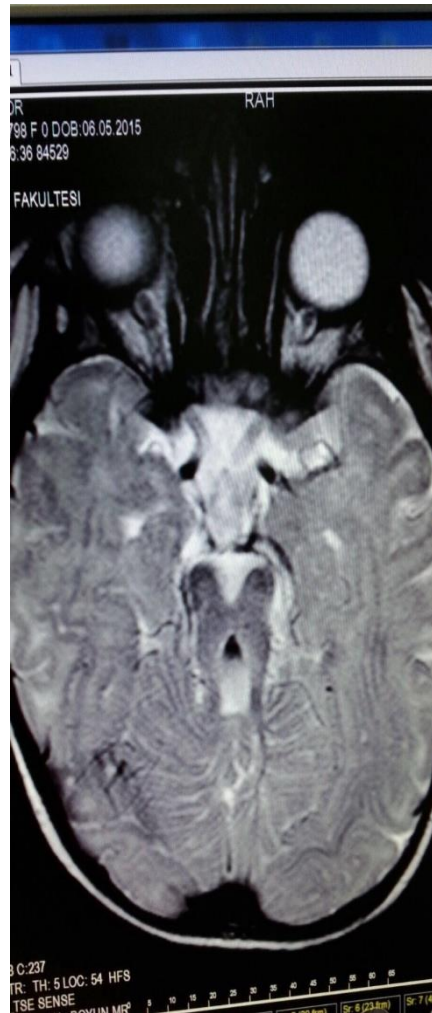


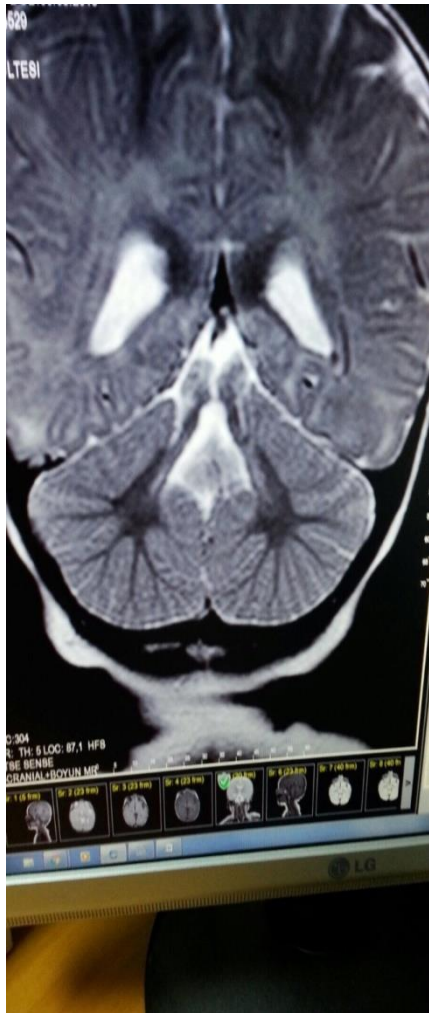24 hafta



Postnatal MR



Dođum Sonrası Tanı

Joubert Sendromu