İskelet Displazileri

Prof Dr Rıza Madazlı

Istanbul Universitesi Cerrahpaşa Tıp Fakültesi

- **Sıklık**
  - **2.4 - 4.5 / 10,000 doğum**
  - **21 / 30 000 doğum (CTF, Prof Dr Beyhan Tüysüz)**

- **Kemik ve kıkırdak / yapısal ve büyüme bozuklukları**
  - **Uzunluk**
  - **Şekil**
  - **Kıvam**

- **Kemik ve kıkırdak**
  - **Yapısal protein – Kollagen**
  - **Osteoblast, Osteoklast Akt/ Büyüme, Morfogenetik Fak**

  ➔Gen Mutasyonları ➔ Isk Displazileri

- **Genetik Hastalıklardır**
  - **436 genetik İ.D.– 364 gen belirlenmiş, 42 grup** (Nosology and classification of genetic skeletal disorders: 2015 revision. Am J Med Genet Part A 167A:2869–2892) **Otozomal dominant, resesif, X-linked resesif, dominant**

Group/Name of Disorder	Inheritance	MIM No.	Locus or Gene	Protein
1. FGFR3 chondrodysplasia group				
Thanatophoric dysplasia type 1 (TD1)	AD	187600	*FGFR3*	FGFR3
Thanatophoric dysplasia type 2 (TD2)	AD	187601	*FGFR3*	FGFR3
Severe achondroplasia with developmental delay and acanthosis nigricans (SADDAN)	AD	187600	*FGFR3*	FGFR3
Achondroplasia	AD	100800	*FGFR3*	FGFR3
Hypochondroplasia	AD	146000	*FGFR3*	FGFR3
Camptodactyly, tall stature and hearing loss syndrome (CATSHL)	AD	610474	*FGFR3*	FGFR3
Hypochondroplasia–like dysplasia(s)	AD, SP			
See also group 33 for craniosynostoses syndromes linked to *FGFR3* mutations, as well as LADD syndrome in group 41 for another *FGFR3*-related phenotype				
2. Type 2 collagen group				
Achondrogenesis type 2 (ACG2; Langer-Saldino)	AD	200610	*COL2A1*	Type 2 collagen
Platyspondylic dysplasia, Torrance type	AD	151210	*COL2A1*	Type 2 collagen
Hypochondrogenesis	AD	200610	*COL2A1*	Type 2 collagen
Spondyloepiphyseal dysplasia congenital (SEDC)	AD	183900	*COL2A1*	Type 2 collagen
Spondyloepimetaphyseal dysplasia (SEMD) Strudwick type	AD	184250	*COL2A1*	Type 2 collagen
Kniest dysplasia	AD	156550	*COL2A1*	Type 2 collagen
Spondyloperipheral dysplasia	AD	271700	*COL2A1*	Type 2 collagen
Mild SED with premature onset arthrosis	AD		*COL2A1*	Type 2 collagen
SED with metatarsal shortening (formerly Czech dysplasia)	AD	609162	*COL2A1*	Type 2 collagen
Stickler syndrome type 1	AD	108300	*COL2A1*	Type 2 collagen
3. Type 11 collagen group				
Stickler syndrome type 2	AD	604841	*COL11A1*	Type 11 collagen alpha-1 chain
Marshall syndrome	AD	154780	*COL11A1*	Type 11 collagen alpha-1 chain
Stickler syndrome type 3 (non-ocular)	AD	184840	*COL11A2*	Type 11 collagen alpha-2 chain
Fibrochondrogenesis	AR	228520	*COL11A1,*	Type 11 collagen alpha-1 chain,
	AR, AD	614524	*COL11A2*	Type 11 collagen alpha-2 chain
Oto-spondylo-mega-epiphyseal dysplasia (OSMED), recessive type	AR	215150	*COL11A2*	Type 11 collagen alpha-2 chain
Oto-spondylo-mega-epiphyseal dysplasia (OSMED), dominant type (Weissenbacher–Zweymüller syndrome, Stickler syndrome type 3)	AD	277610	*COL11A2*	Type 11 collagen alpha-2 chain
See also Stickler syndrome type 1 in group 2				

- DNA test

10 - 173 gen

  - FGFR3 mutasyon (achondroplasia, hypochondroplasia thanatophoric dysplasia)
  - COL1A1 ve COL1A2 mutasyon (osteogenesis imperfecta, achondrogenesis, hypochondrogenesis).

Skeletal Dysplasia	Prevalence per 100,000 Births
LETHAL DYSPLASIAS	
Thanatophoric dysplasia	2.4 to 6.9
Achondrogenesis	0.9 to 2.3
Osteogenesis imperfecta type IIA	1.8
Hypophosphatasia congenita	1.0
VARIABLE-PROGNOSIS DYSPLASIAS	
Rhizomelic chondrodysplasia punctata	0.5 to 0.9
Campomelic dysplasia	1.0 to 1.5
Asphyxiating thoracic dystrophy	0.8 to 1.4
Ellis–van Creveld syndrome	0.7
Osteogenesis imperfecta (other types)	1.8
NONLETHAL DYSPLASIAS	
Heterozygous achondroplasia	3.3 to 3.8
OVERALL	24.4 to 75.0

The Fetal Musculoskeletal System

Phyllis Glanc, David Chitayat, and Sheila Unger

- **En sık**
  - **Heterozigoz Akondroplasia**
  - **Tanatotrofik displasi**
  - **Osteogenesis Imperfekta**
  - **Akondrogenesis**

Tanımlar

- Rizomeli / Proksimal
- Mesomeli / Orta
- Akromeli / Distal
- Mikromeli / Ekstremite

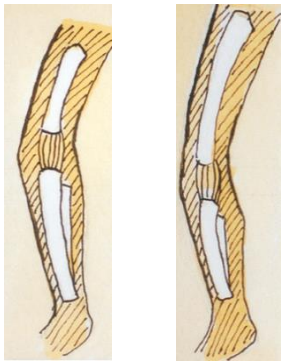

Rizo Meso

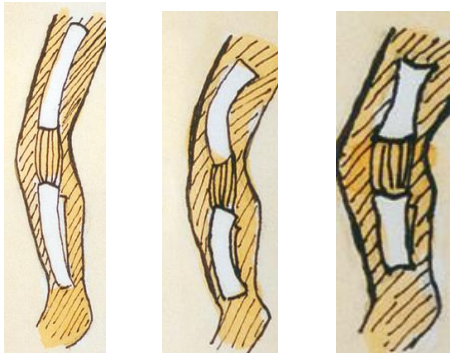

Mikro

- Polidaktili
- Sindaktili
- Clinodaktili

- Talipes
- Rocker - Bottom foot

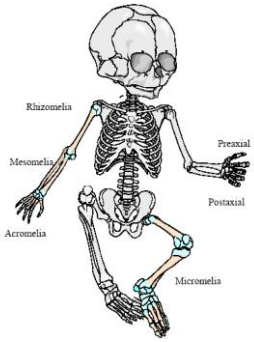

- Diastrophic / Dönmüş
- Campomelic / Eğilmiş
- Metatropic / Değişen
- Kyphomelic / Öne eğilmiş
- Thanotropic / Ölüm getiren
- Spondylo- / Spine

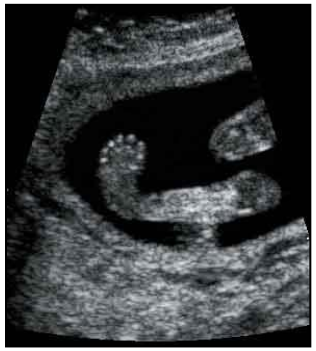

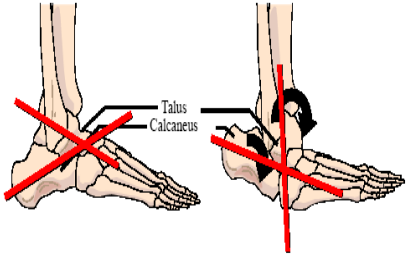

Prenatal Tanı

- Zor / “Puzzle”
- Tecrübe
- Ekip
  - Perinatalog
  - Genetik
  - Radyolog
  - Patolog

- %50-60 Antenatal belirti verir
- USG
  - belirleme %85-95
  - Kesin Tanı (Adının belirlenmesi) - %40-55
- 3D-4D USG
- fMRI
- Maternal kanda cffDNA

- **Aile Hikayesi**
  - **Ailede var**
  - **Kendi doğurmuş**

  ➔ Indeks vaka adı konmuş olmalı / Neyi aradığımızı biliyoruz

- **Mevcut gebelikte İskelet sorunu**

Yaklaşım

1. **Uzun kemiklerin değerlendirilmesi**
2. **Eller ve ayaklar**
3. **Baş ve yüz**
4. **Göğüs kafesi**
5. **Omurga**
6. **Diğer kemikler**
7. **Polihidramnios, NIHF**
8. **Diğer sistem anomalileri**

1. Ekstremiteler – Uzun Kemikler

- **Uzun kemikler bakılmalı**
  - **3 kemik / Üst ekstremite**
  - **3 kemik / Alt ekstremite**

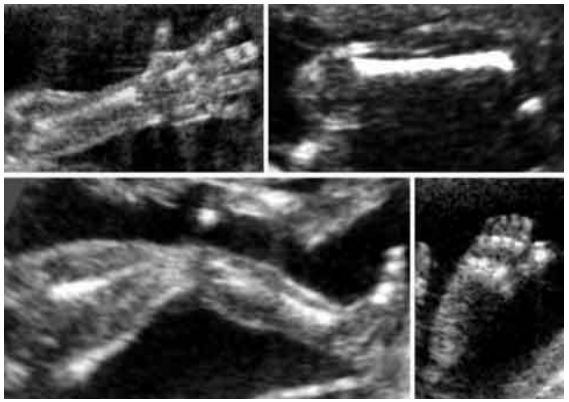

Femur Ölçümü

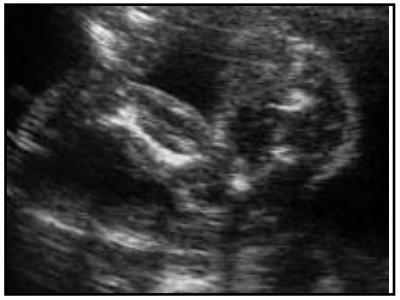

- FL<2sd
  - Yapısal
  - FGK
  - Kromozom
  - **Iskelet Displasi / 2sd-5mm, bowing**

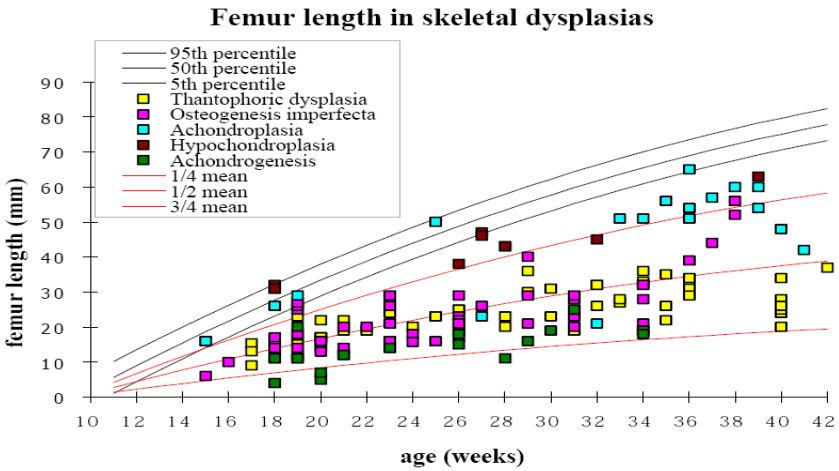

- Gelişim Hızı
  - 16-22 gh / 2.5-2.7mm /hf
  - OI / 15-16gh
  - Het. Achondroplasia- 27 gh

- Oranlar
  - FL /HC < -3sd
  - FL/Foot < 0.87

Diğer Uzun Kemik Ölçümleri

Kısalık Tip	Ayırıcı Tanı
Rizomeli	Achodroplasia Chondrodysplasia punctata Diastrophic dysplasia Thanatophoric dysplasia Kısa femur
Mesomelia	Ellis-van Creveld syndrome Mesomelic dysplasia
Mikromelia	Achondrogenesis Atelosteogenesis Diastrophic dysplasia Fibrochondrogenesis Kniest dysplasia SRPD (I, III) Osteogensis imperfecta (II)



Mineralizasyon (Ekojenite)

- Akustik gölgelenme
  - Kalvaryum
  - Kaburga
  - Uzun kemikler

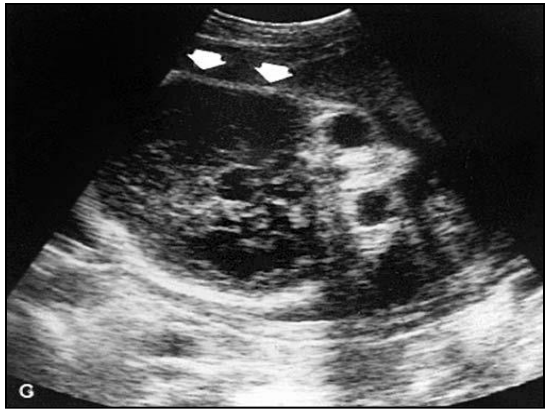

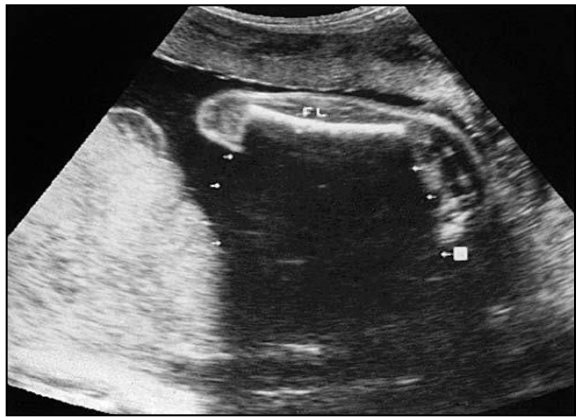

- Hipominerilizasyon
  - Achondrogenesis
  - Hypophosphatasia
  - Osteogenesis imperfecta
- Hipermineralizasyon
  - Osteopetrosis

Kırıklar

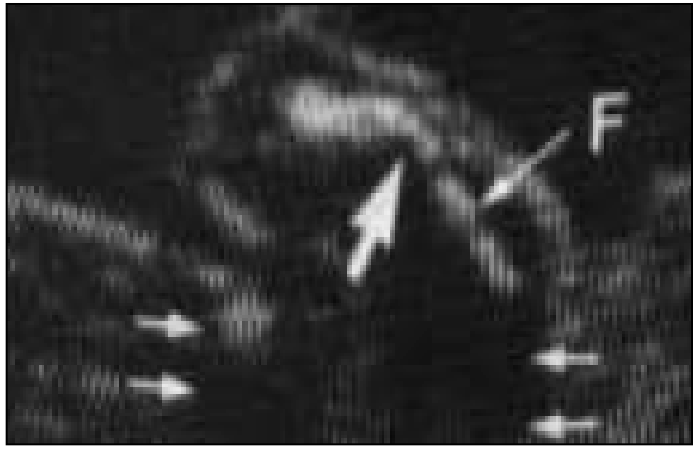

Osteogenesis İmperfecta

Eğim (Bowing)

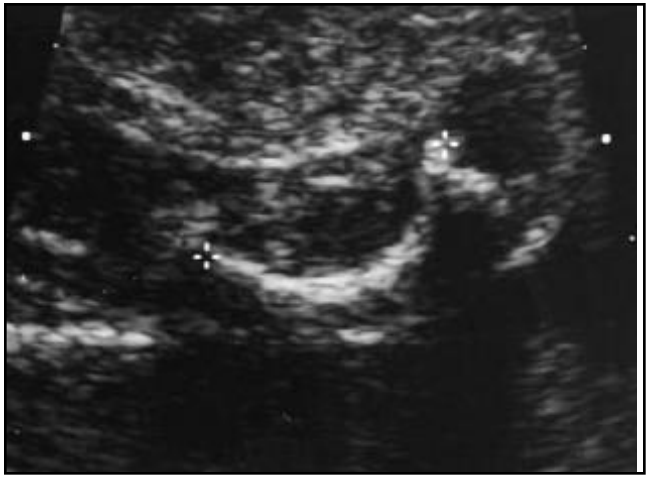

- Thanatophoric dysplasia
- Campomelic dysplasia
- Osteogenesis imperfecta

2. Eller /Ayaklar

- **Polidaktili**
  - Asphyxiating thoracic dystrophy (Jeune syndrome)
  - Short-rib-polydactyly syndrome
  - Chondroectodermal dysplasia
- **Sindaktili**
  - Apert's syndrome
  - Jarcho-Levin syndrome
  - Robert's syndrome
- **Talipes**
  - Campomelic dysplasia
  - Diastrophic dysplasia
  - Osteogenesis imperfecta

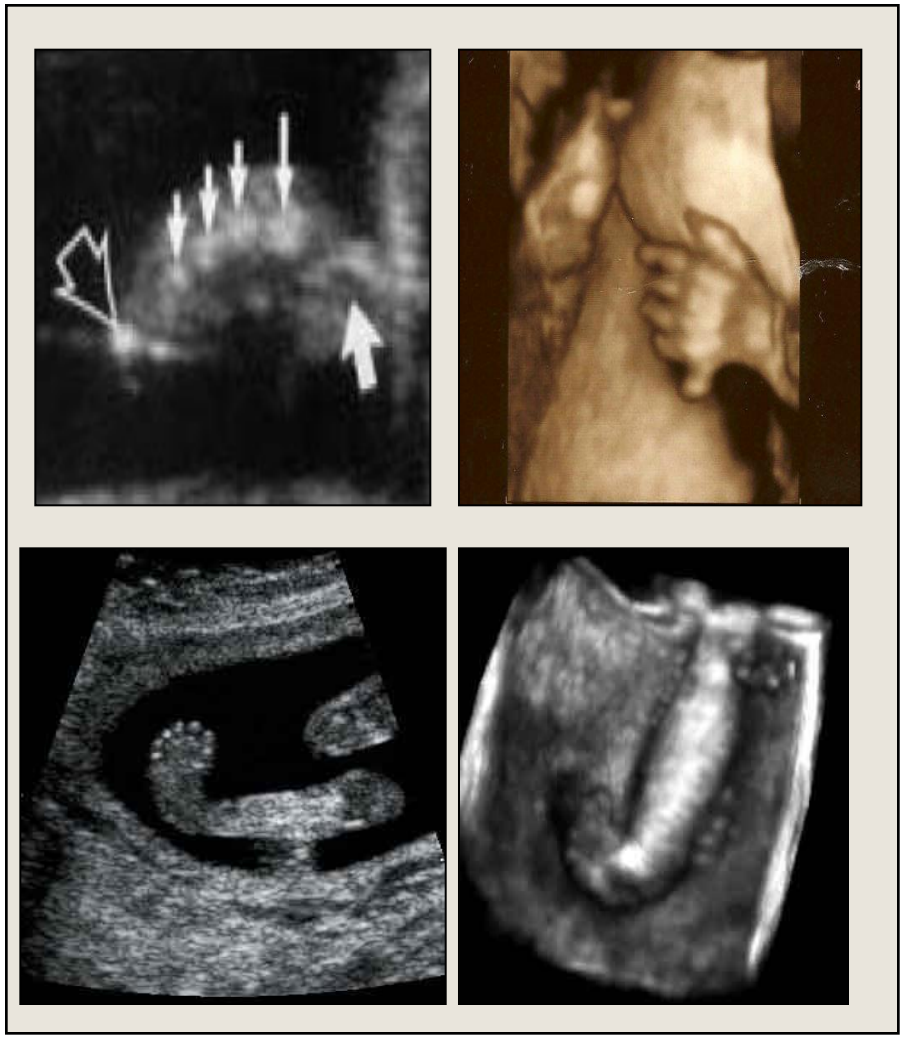

3. Kafa

Baş Şekli

- Frontal bossing
  - Thanatophoric dysplasia
  - Osteogenesis imperfecta
- Cloverleaf skull
  - Homozygous achondroplasia
  - Thanatophoric dysplasia
- Craniosynostosis
  - Carpenter's syndrome
  - Hypophosphatasia
  - Acrocephalosyndactyly
  - Crouzon – Aperts

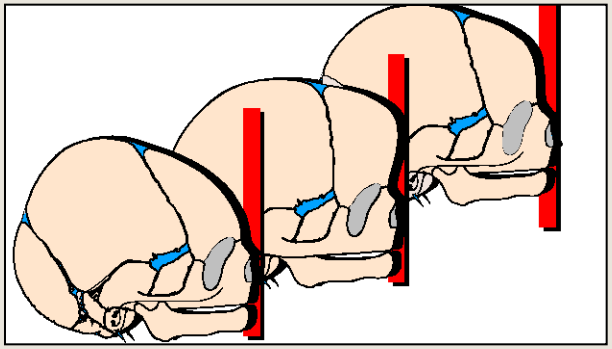

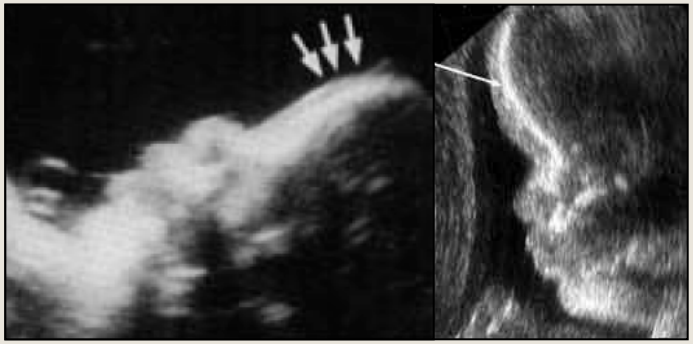

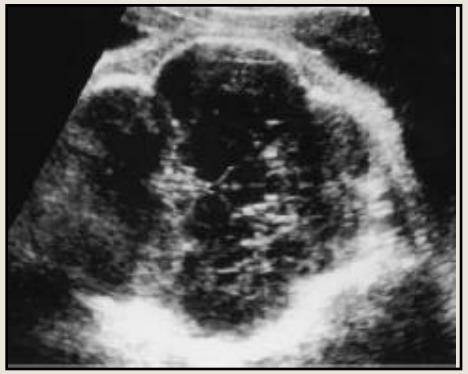

Yüz

- Göz
  - Hipo ve hipertelorizim (Üçler Kuralı)
- Mikro-retrognati
- Yarık dudak, damak
- Kulaklar

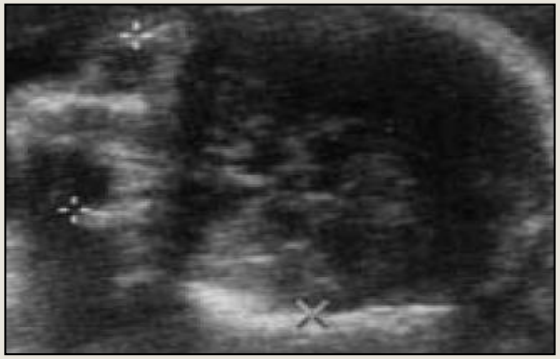

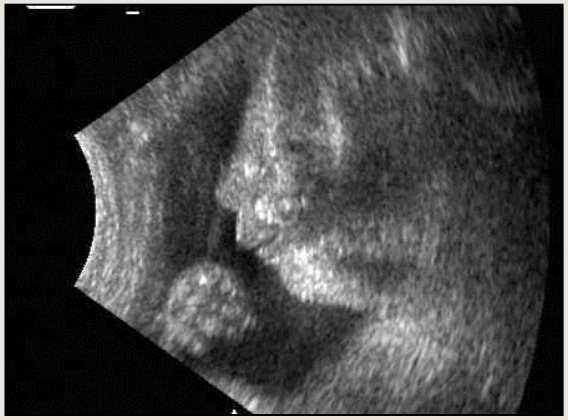

4. Göğüs

- GÇ / AÇ ➔ % 80-100
- Lethal İskelet Displazi / < % 60

- Dar thoraks
  - Achondrogenesis
  - Hypophosphatasia
  - Campomelic dysplasia
  - Chondroectodermal dysplasia
  - Osteogenesis imperfecta
  - Short-rib polidaktili
  - Asphyxiating thoracic dysplasia

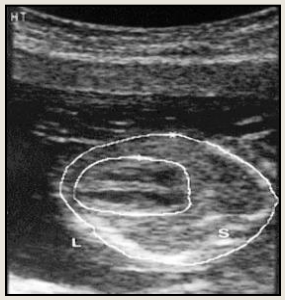

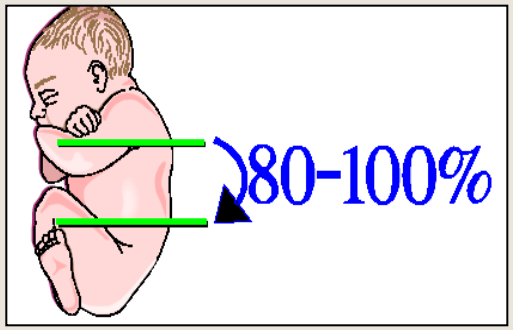

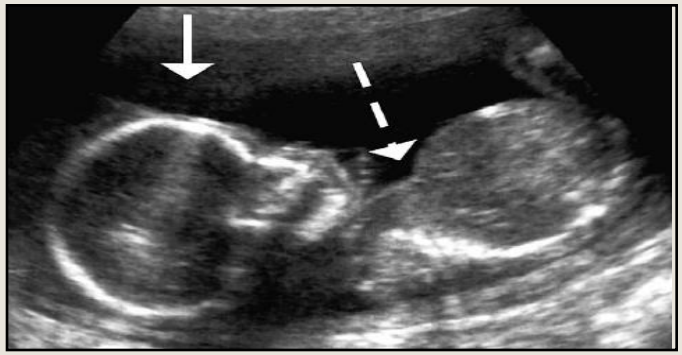

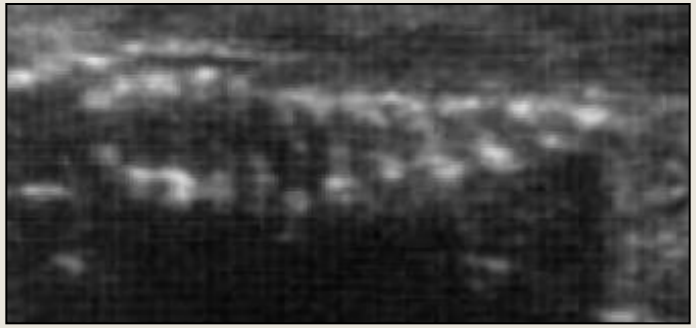

5. Omurga

- **Platyspondyly – Omurganın düzleşmesi**
  - **Thanatophoric dysplasia**
  - **Achondroplasia**
- **Hipominerelizasyon-**
  - **Achondrogenesis**
- **Hemivertebra –**
- **Kyphosis**
- **Scoliosis**

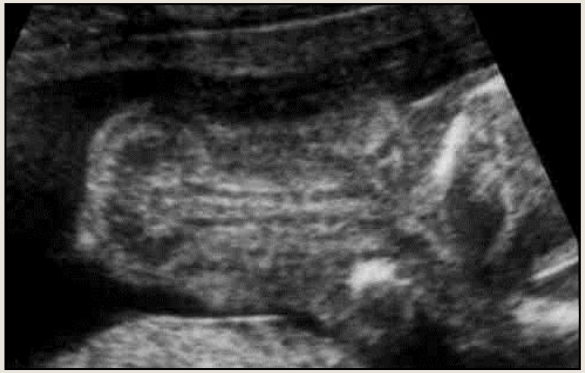

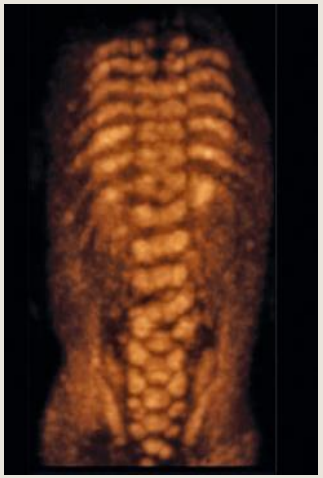

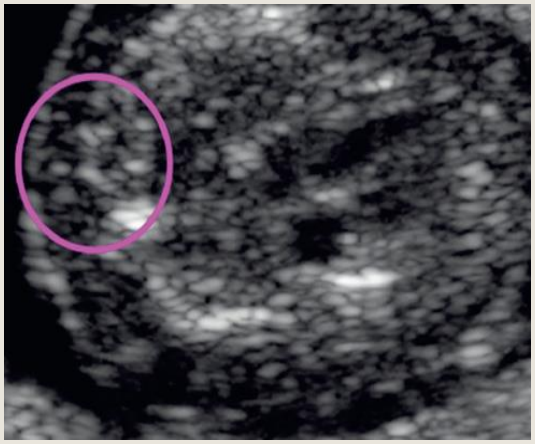

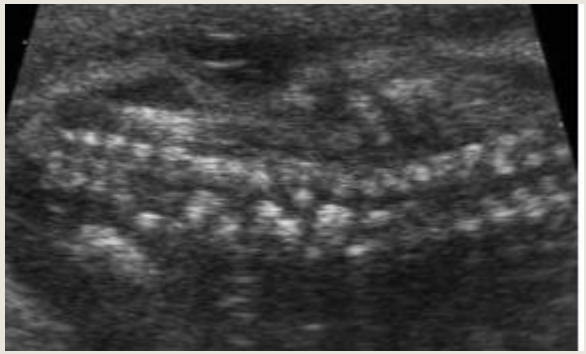

6. Diğer Kemikler

- Scapula
  - Campomelic dysplasia
- Klavikula
  - Kısa / Cleidocranial dysplasia
- Kaburga
  - Kısa / SRPS
  - Sayı / 11 çift- Campomelic dysplasia, Cleidocranial dysplasia, Trisomy 18
- İliac kemikler

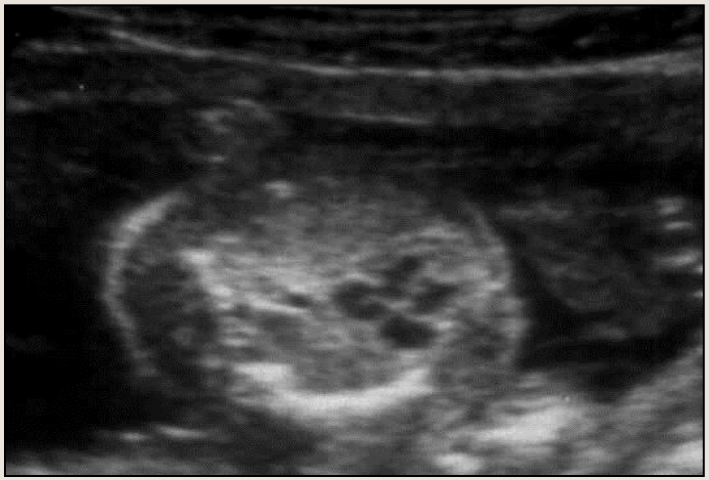

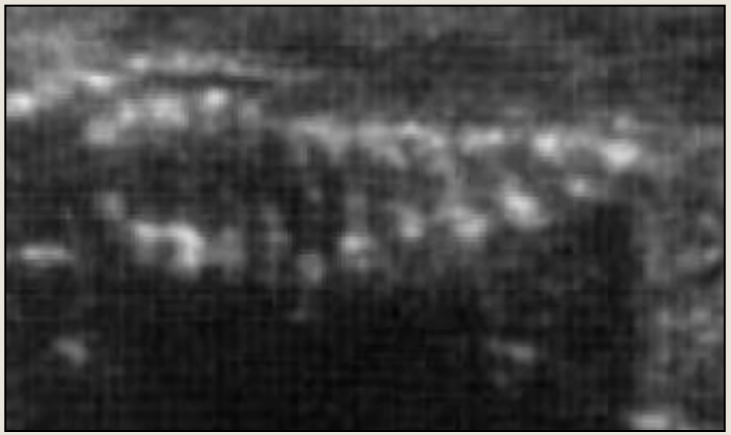

7. Diğer Anomaliler

- Polihidramnios
  - Thanatophoric dysplasia
  - Achondroplasia
  - Chondrodysplasia punctata
  - Short-rib-polydactyly syndrome
  - Achondrogenesis
- NIHF
- Diğer Sistemler – Kalp, Böbrek
- Fetal Hareketler

Lethal Displaziler

- **Göğüs Çevresi / Abdomen Çevresi oranı $\leq$ 0. 6**
- **Femur Uzunluğu / Abdomen Çevresi oranı $\leq$ 0.16**
- **Erken başlangıç**
- **Ağır mikromeli, bowing, kırıklar**
- **Polihidramnios**

Postnatal

- Ekip
  - Perinatolog
  - Genetisyen
  - Patalog
- Fizik muayene
- Radyografi
- Histolji / Otopsi
- Kromozom / Spesifik sitogenetik çalışmalar
- DNA saklanmalı
- Cilt biyopsi – kollegen çalışmaları
- Biyokimyasal - Enzimatik çalışmalar

MİKROMELİ



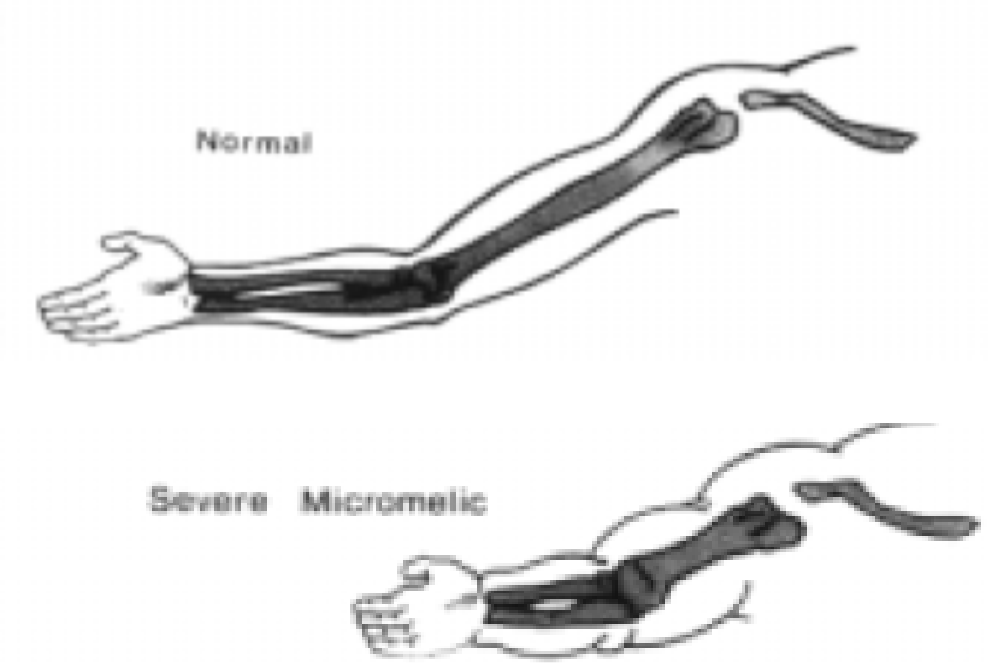

Achondrogenesis

	Tip 1	Tip2
Uzun Kemik	<%30	Değişken
Kırık	Nadir	?
El ve Ayak	Kısa	
Toraks	Dar, kısa, kaburga kırık	?, Kaburga kırık yok
Skull	Makrocrania	
Omurga	Ossf.yok	Ossf.yok
Minerali zasyon	Kafa, omurga hipominera.	Kafa normal, Omurga hipo
Gen Mutasyon	DTDST OR	COL2A1 OD
Diğer	Hidrops, Polihidramn	

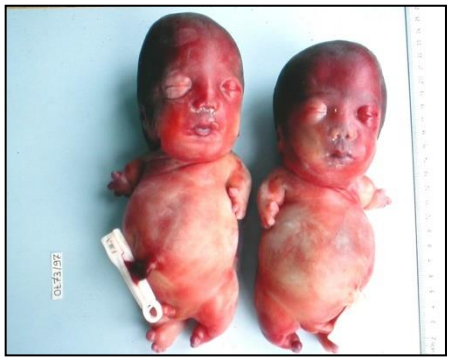

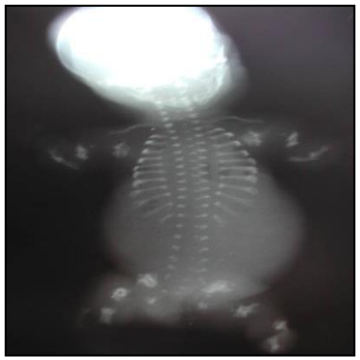

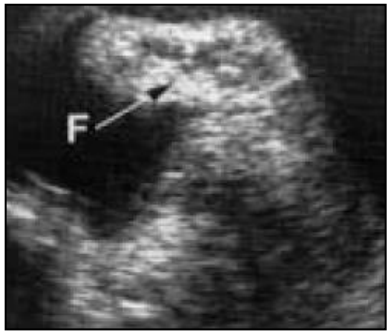

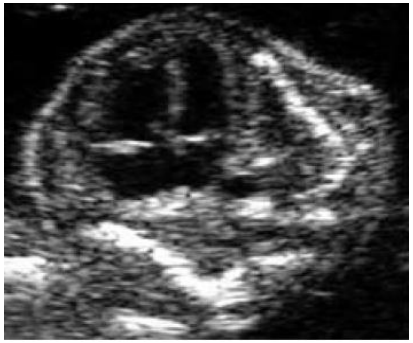

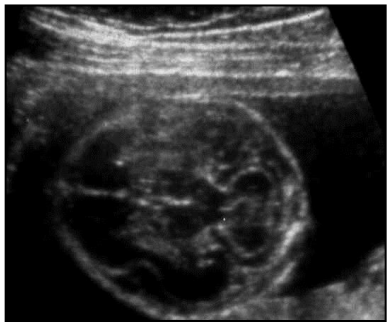

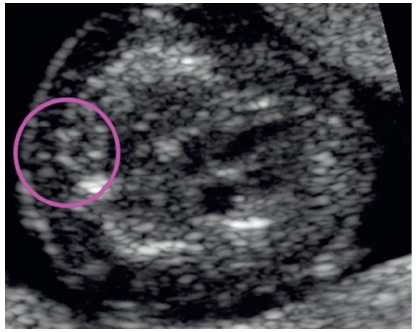

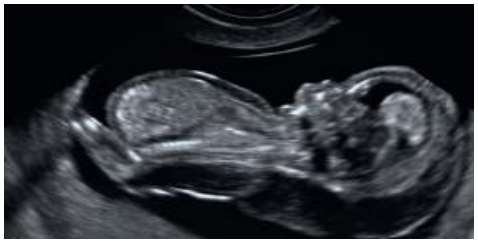

Osteogenesis Imperfecta

	Tip 1 (Hafif)	Tip2 (Letal)	Tip 3 (Ağır)
Uzun Kemik	Normal	%30-80	%80-100, Progresif
Kırık	Nadir	Multiple	Multiple
El ve Ayak	Kısa	Kısa	Kısa
Toraks	?	Dar,kısa	Dar,kısa
Skull		Hipomi nerilaz	Hipomi nerilaz
Omurga		Platyspod	
Minerali zasyon	Kafa 3.trm	Kafa hipo	Kafa hipo
Gen Mutasyon	COL1A1 COL1A2 OD	COL1A1 COL1A2 OD, OR	COL1A1 COL1A2 OD,OR
Diğer	Mavi sklera	Mavi sklera	Mavi sklera

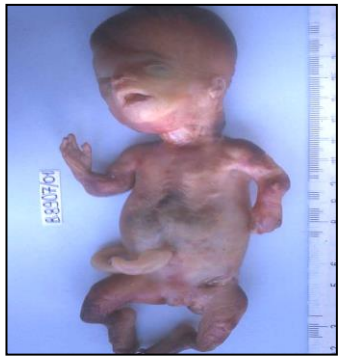

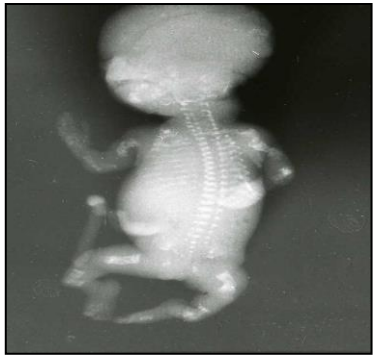

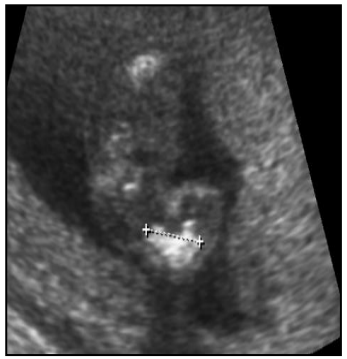

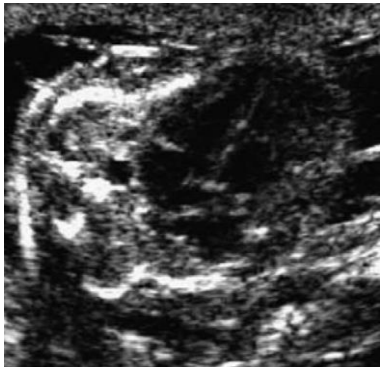

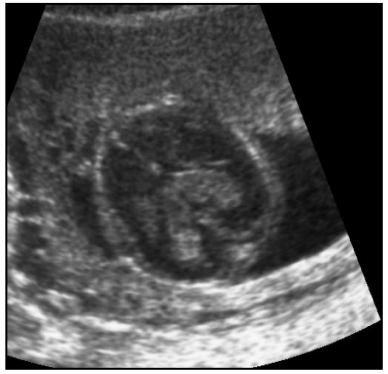

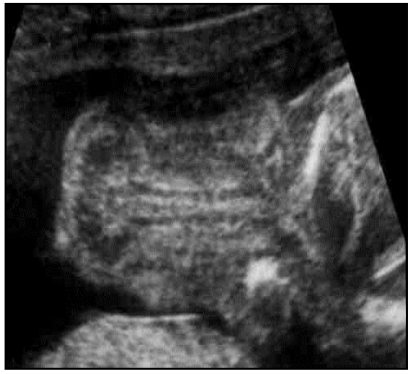

Hypophosphatasia

Uzun Kemik	<%30
Kırık	Nadir
El ve Ayak	Kısa
Toraks	Dar, kısa rib
Skull	Hipomineralizasyon
Omurga	Hipomineralizasyon
Mineralizas yon	Kafa,omurga, yamalı
Gen Mutasyon	ALPL OR
Diğer	Polihidramnios

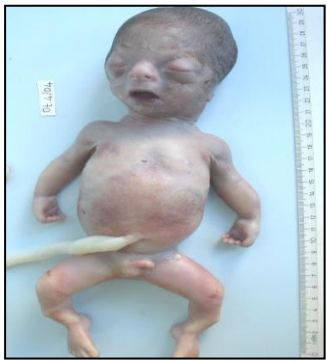

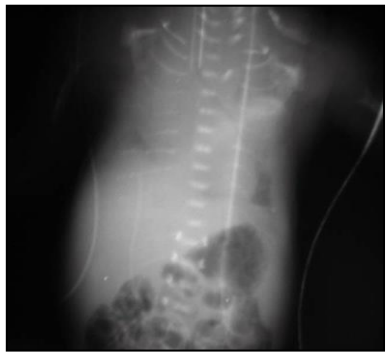

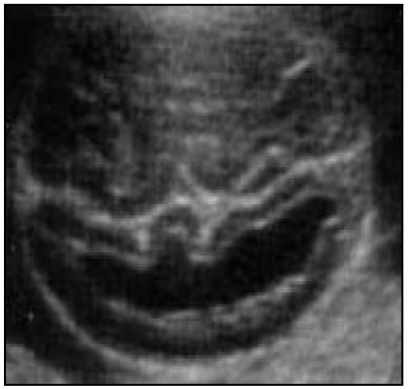

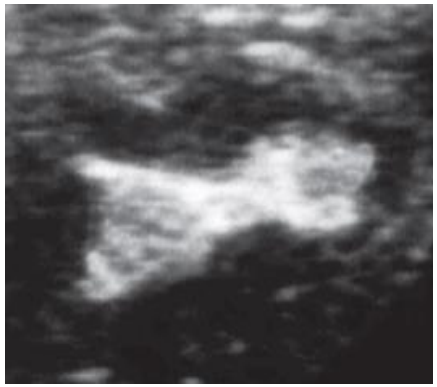

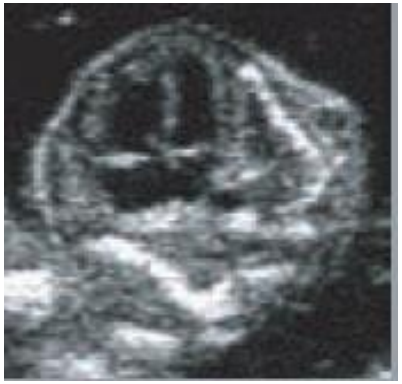

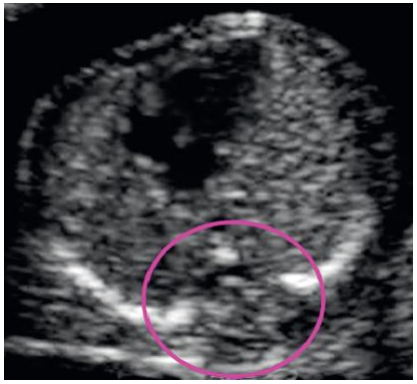

Short Rib Polidaktili Sendromu

Uzun Kemik	<%30
Kırık	Yok
El ve Ayak	Polidaktili
Toraks	Dar, kısa rib
Skull	Normal
Omurga	Normal
Mineralizasyon	Normal
Gen Mutasyon	DYNC2H1 OR
Diğer	Kardiak, GU anomali

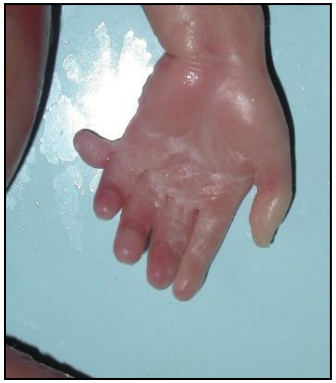

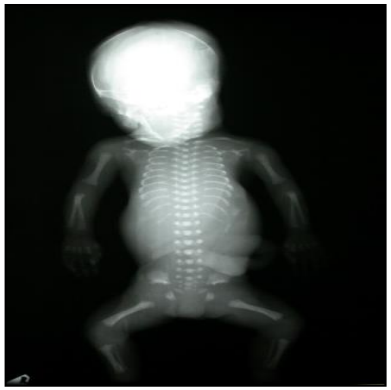

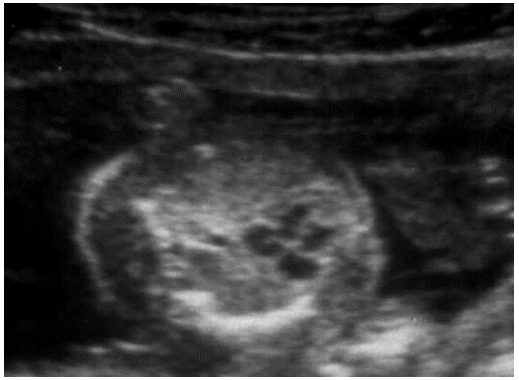

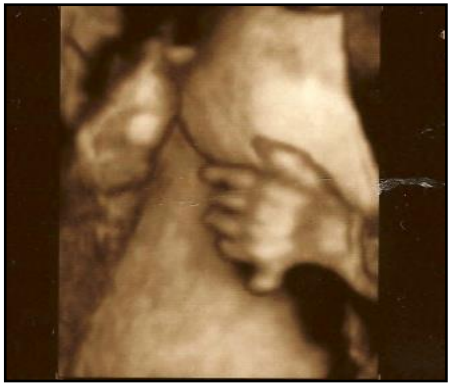

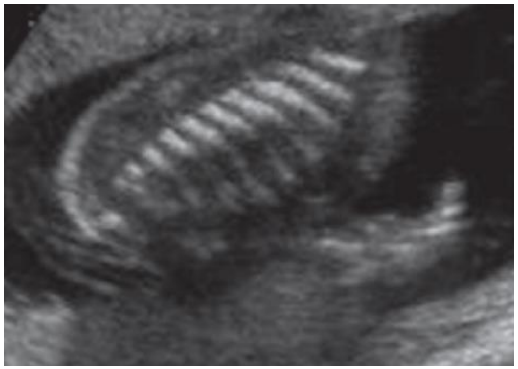

Atelosteogenesis

Uzun Kemik	<%30
Kırık	Belirgin değil
El ve Ayak	Kısa deformite
Toraks	Dar, kısa rib
Skull	Düz, Fasial cleft
Omurga	Normal
Mineralizasyon	Azalmış
Gen Mutasyon	FLNB OD
Diğer	

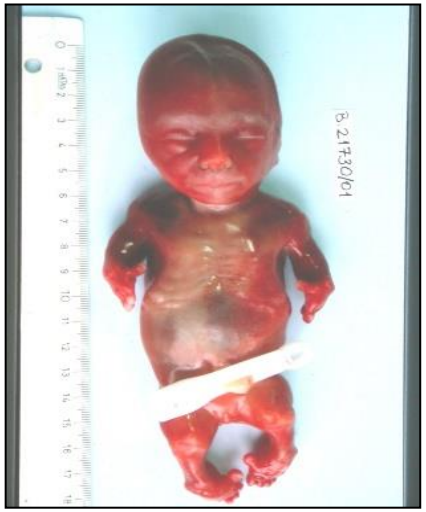

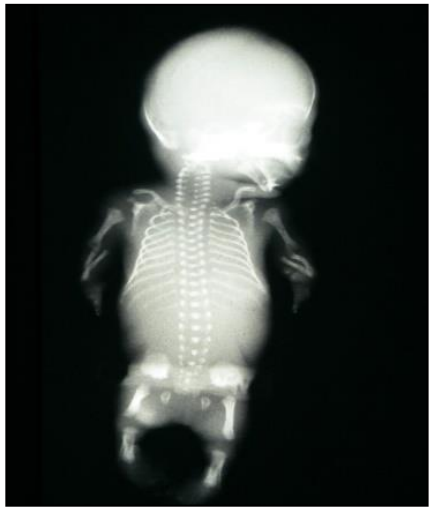

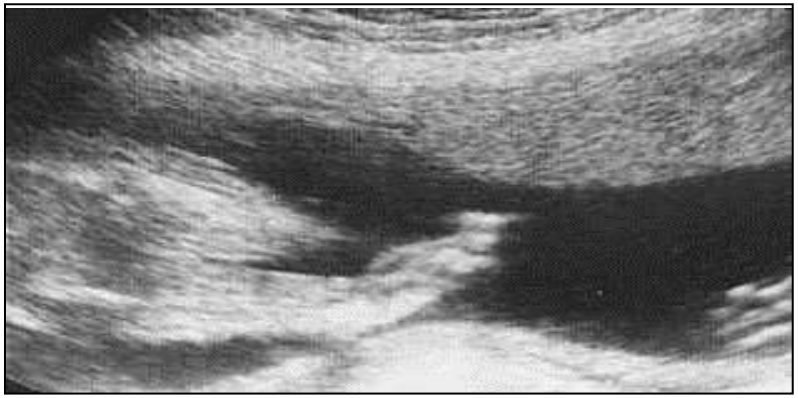

Asphyxiating Thoracic Dystrophy (Jeune)

Uzun Kemik	%30-80 / Mikromelik
Kırık	Yok
El ve Ayak	Polidaktili
Toraks	Dar, Uzun, Kısa rib
Skull	Yarık dudak
Omurga	Normal
Mineralizasyon	Normal
Gen Mutasyon	DYNC2H1 OR
Diğer	Uriner sist anomali

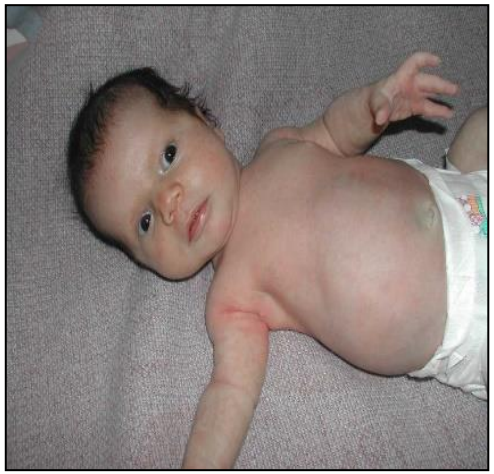

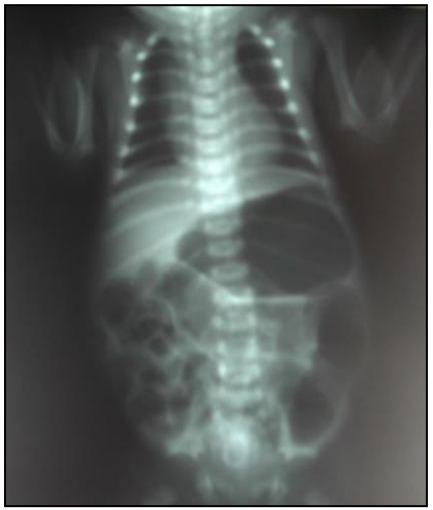

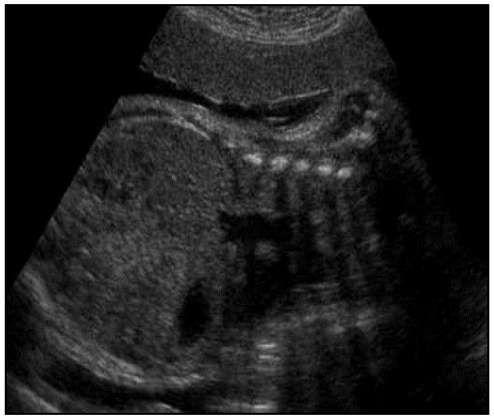

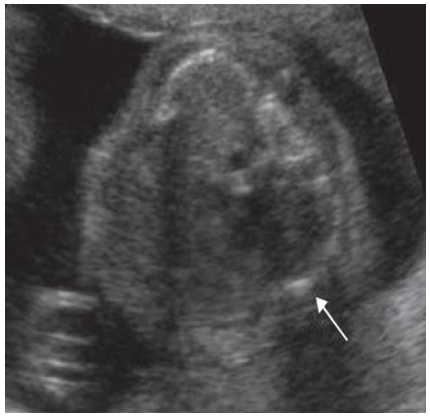

Greenberg Dysplasia

SHORT COMMUNICATION

Prenat Diagn 2001; **21**: 65–67.

Detailed ultrasonographic findings in Greenberg dysplasia

Riza Madazli*, Figen Aksoy, Vildan Ocak and Turgay Atasü

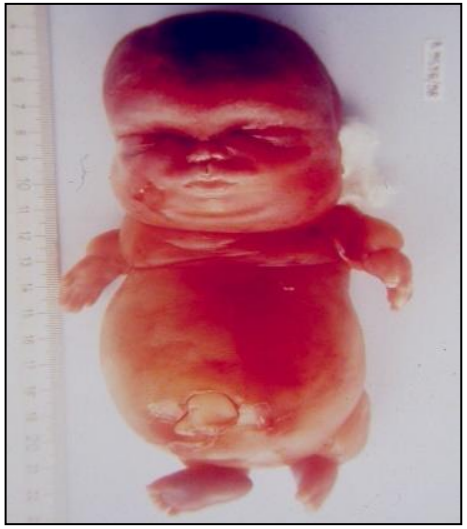

- **Mikromelia**
- **Dar thoraks**
- **Güveyeniği görünümü**

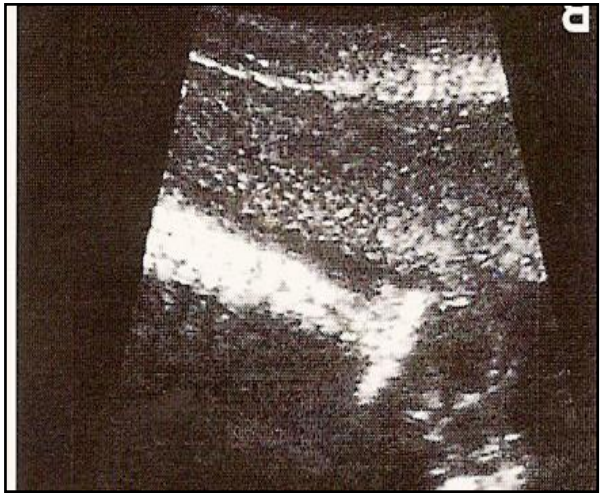

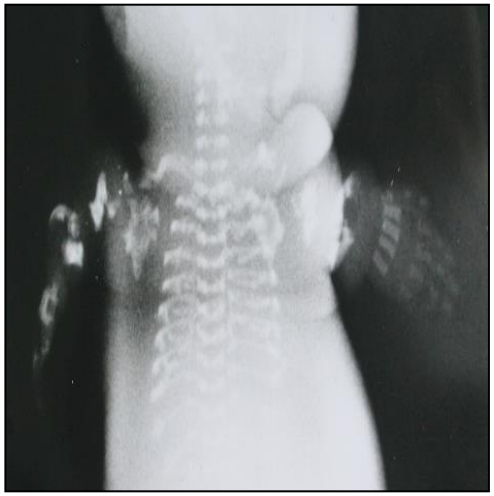

• RİZO-MİKROMELİ

Thanatophoric Displasia

Uzun Kemik	%30-80 /Rizomelik /Mikromelik Eğimli " telephone receiver"
Kırık	Yok
El ve Ayak	Kısa
Toraks	Kısa rib, Dar değil
Skull	Cloverleaf skull, frontal bossing
Omurga	Platyspondly
Mineralizasyon	Omurga azalmış
Gen Mutasyon	FGFR3 OD
Diğer	Polihidramnios

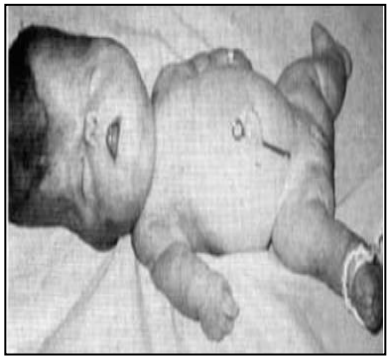

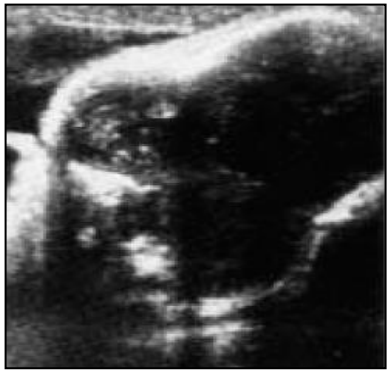

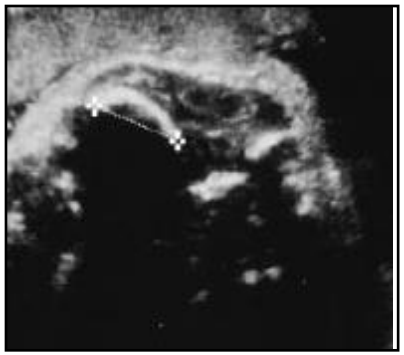

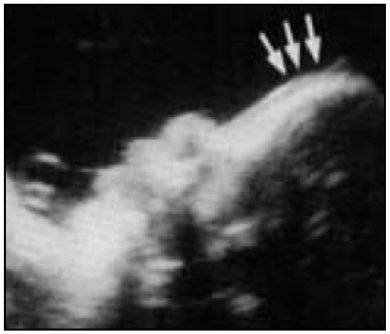

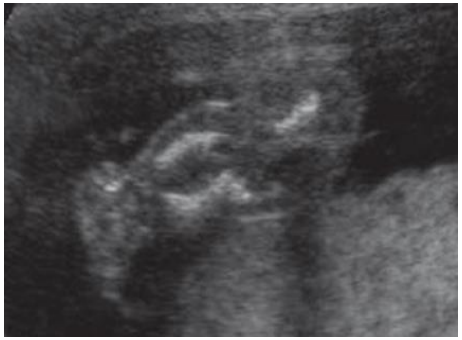

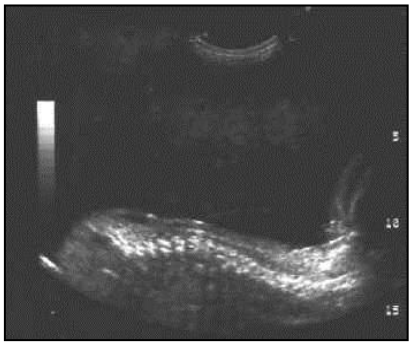

Campomelic Displasia

Uzun Kemik	%30-80 /Rizomelik /Mikromelik Eğimli (bowed) uzun kemikler
Kırık	Yok
El ve Ayak	Talipes
Toraks	Hipoplastik skapula
Skull	Mikrognati
Omurga	Normal
Mineralizasyon	Normal
Gen Mutasyon	SOX9 OD
Diğer	Diğer sistem anomali Polihidramnios

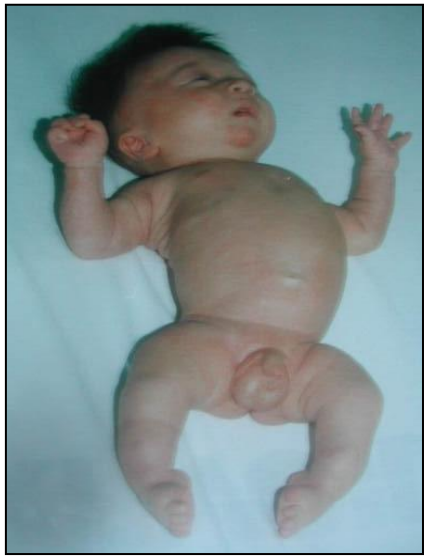

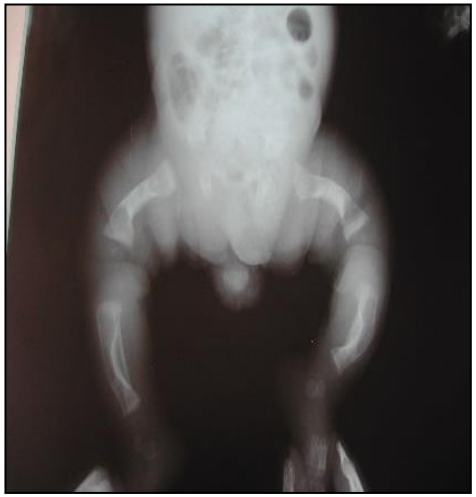

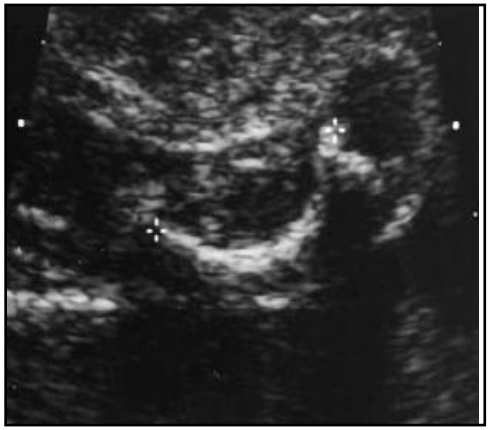

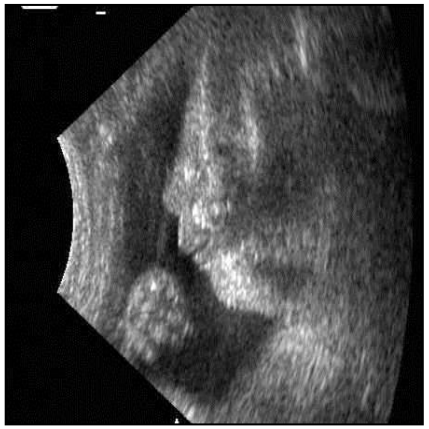

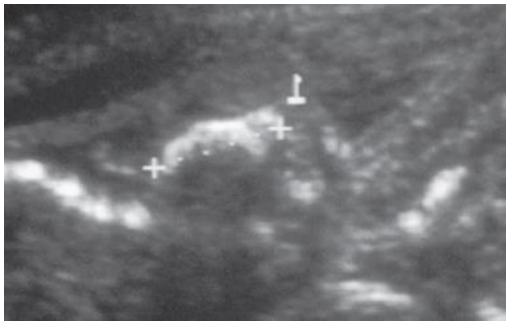

Achondroplasia

	Heterozigot	Homozigot
Uzun Kemik	Rizomelik (>24 gh / alt ekst. önce)	Ağır Rizo-mikromeli
Kırık	Yok	Yok
El ve Ayak	Parmaklar eşit uzunluk	Kısa
Toraks	Normal	Dar
Skull	Frontal bossing, burun kökü basık	Frontal bossing, burun kökü basık
Omurga	Normal	Normal
Minerali zasyon	Normal	Normal
Gen Mutasyon	FGFR3 OD	FGFR3 OD
Diğer	Polihidramn	Polihidramn

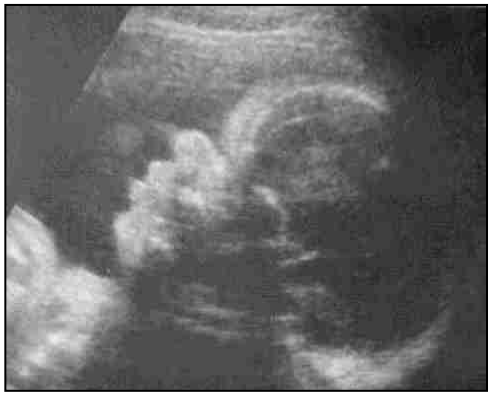

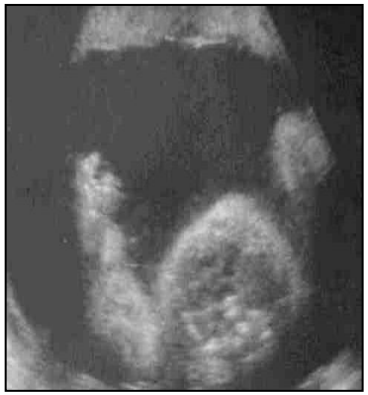

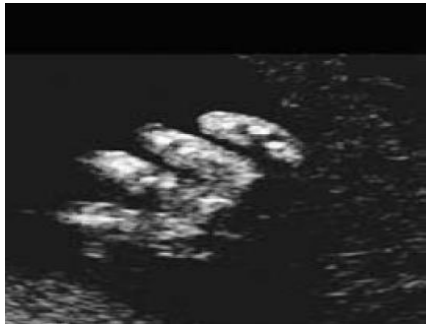

Diastrophic Dysplasia

Uzun Kemik	%30-80 /Rizomelik
Kırık	Yok
El ve Ayak	Talipes, deformiteler
Toraks	Normal
Skull	Mikrognati, YD
Omurga	Kifo-skolyoz
Mineralizasyon	Azalmış
Gen Mutasyon	DTDS1 OR
Diğer	Uriner sist anomali

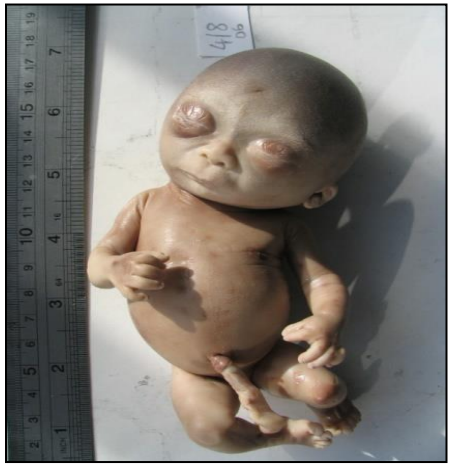

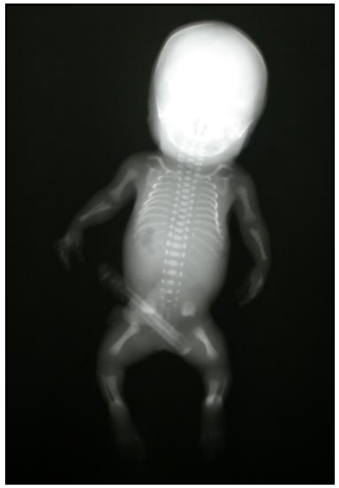

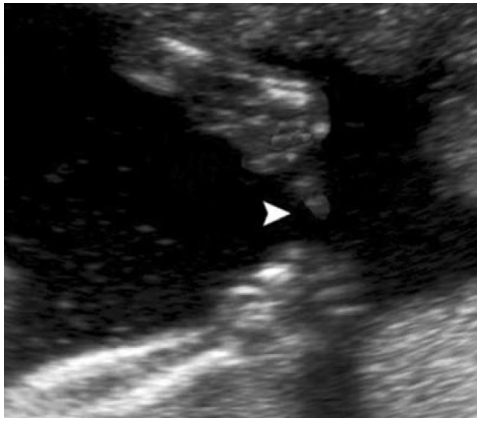

Chondrodysplasia Punctata

Uzun Kemik	%30-80 /Rizomelik Epifizel ossifikasyon
Kırık	Yok
El ve Ayak	Normal
Toraks	Normal
Skull	Mikrognati, mikrosefali
Omurga	Kifo-skolyoz, perivertebral ossifikasyon
Mineralizasyon	Normal
Gen Mutasyon	PEX7 OR
Diğer	Mental retardasyon

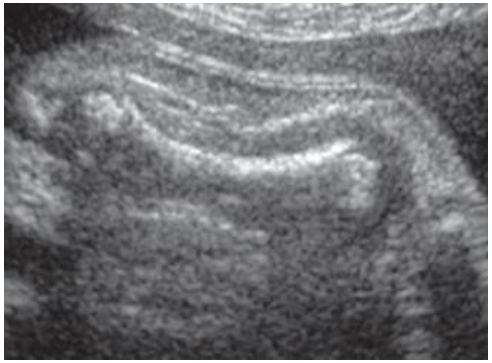

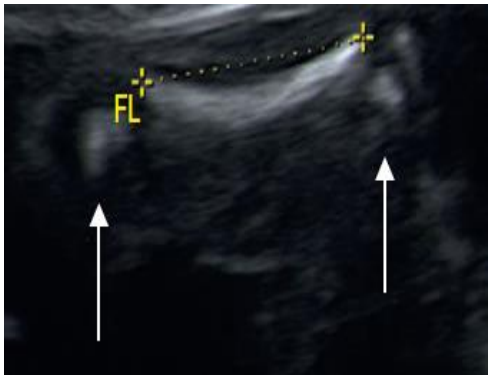

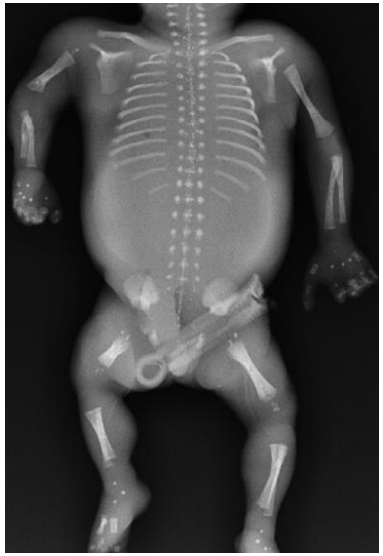

Teşekkürler